REGEDENT
smart regeneration

# THE Graft

Natural bone augmentation

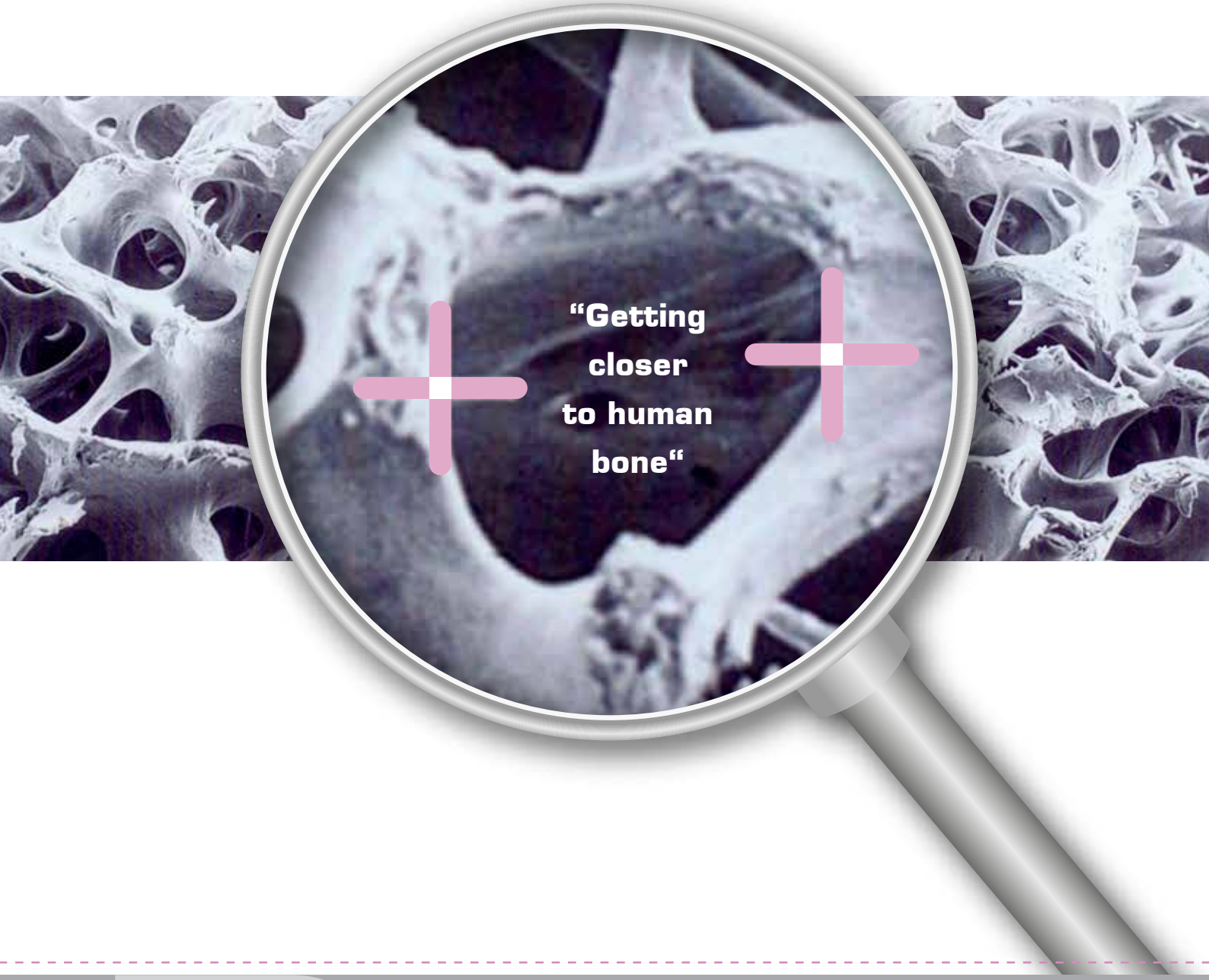

# THE GRAFT

## Natural bone augmentation — "Getting closer to human bone"

THE Graft is a natural, mineralized bone augmentation material made from deproteinized porcine cancellous bone. Due to its porcine origin, THE Graft is structurally similar to human tissue.[1,2] It has the highest possible level of porosity combined with a natural interconnectivity.[3]
Thanks to the patented manufacturing process, potentially immunogenic organic elements are removed very effectively while the native material structure is optimally maintained.

- **OPTIMAL VOLUME RETENTION**
  Native natural structure of the porcine cancellous bone ensures stabilization of the defect and improves bone regeneration.[4]

- **INCREASED EFFICIENCY**
  High porosity and early remodelling improves clinical performance.[3]

- **SAFE & BIOCOMPATIBLE**
  Optimized safety and biocompatibility profile thanks to the combination of porcine origin and a highly efficient preparation process.[3]

# OPTIMAL VOLUME RETENTION

## Native natural structure ensures defect stabilization and improved bone regeneration

THE Graft has a high specific surface area allowing more bone apposition.[3] The clinical potential of THE Graft has been confirmed in an *in vivo* pre-clinical study. Rabbit calvarial defects were filled with either THE Graft or natural DBBM and covered with resorbable collagen membranes.[4]

Ingrowth of blood vessels and connective tissue as well as the regeneration of immature woven bone were observed in week 2. In week 8, a large number of osteoblasts and new bone were observed around the augmentation material in particular for THE Graft. At the same time, the amount of residual particles was lower for THE Graft than for DBBM, indicating that THE Graft was partially resorbed and remodelled.

### Augmentation volumes

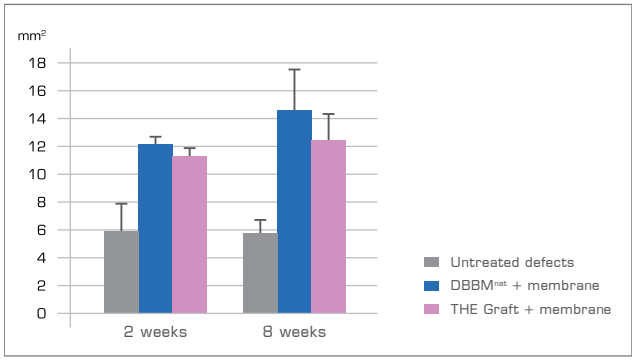


THE Graft shows an *in vivo* volume retention in an augmented calvarial defect comparable to natural DBBM.

### Newly formed bone

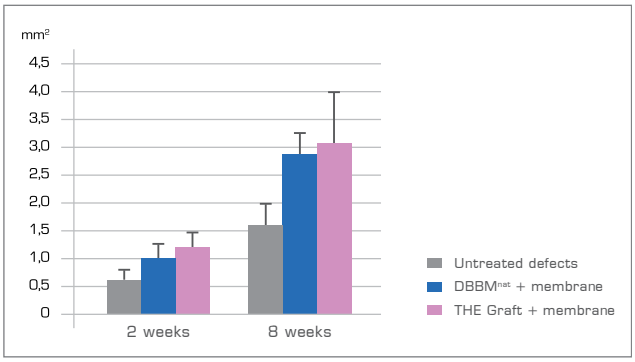


Augmentation with THE Graft results in a slightly higher formation of new bone compared to DBBM (not statistically significant).

# INCREASED EFFICIENCY

## High porosity and early remodelling improve clinical performance

With 72.4 %, THE Graft has a higher level of porosity than comparable preparations of bovine origin (63.5 %–71.2 %), and almost reaches the level of human bone (76.5 %).[3,5]

The high porosity of THE Graft results in a quicker absorption of liquids (e.g., blood) in comparison to natural DBBM.[3] This not only facilitates the application of the material but is also clinically relevant.

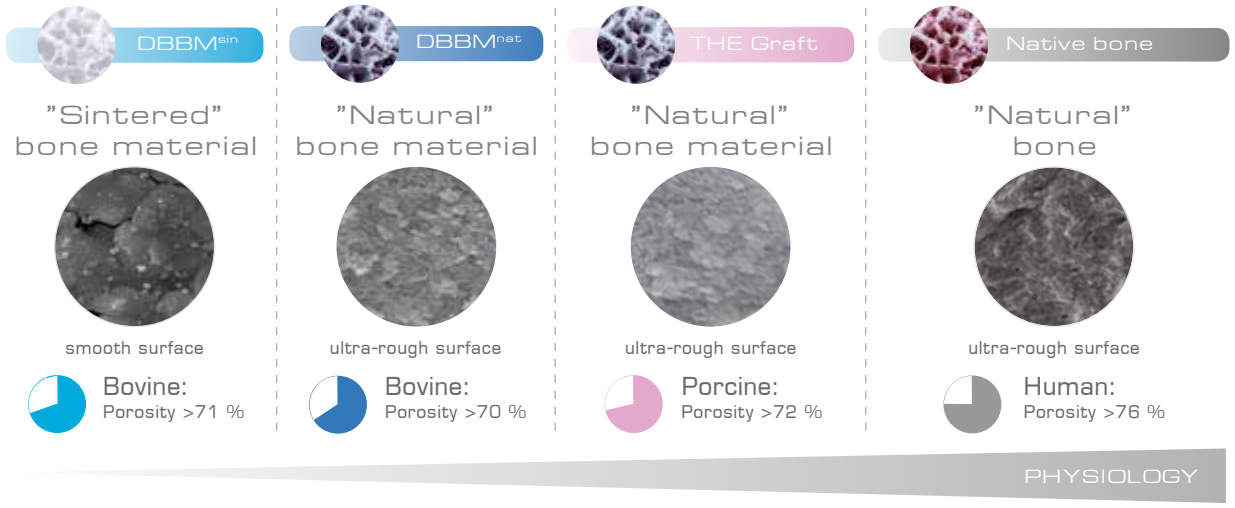


In a comparative study, rabbit calvarial defects were filled with either THE Graft or natural DBBM and covered with a non-resorbable PTFE membrane.[3]

THE Graft showed a consistently higher rate of new bone formation than natural DBBM, particularly in the later study period after 8 weeks. The newly formed bone in the THE Graft test group also showed a much better bone quality than in the control group with DBBM (illustrated by a higher ratio of mature lamellar bone to loose woven bone for THE Graft versus DBBM (14.8 ± 11.3 versus 3.3 ± 2.0)), which indicates the early remodelling.

Vital bone

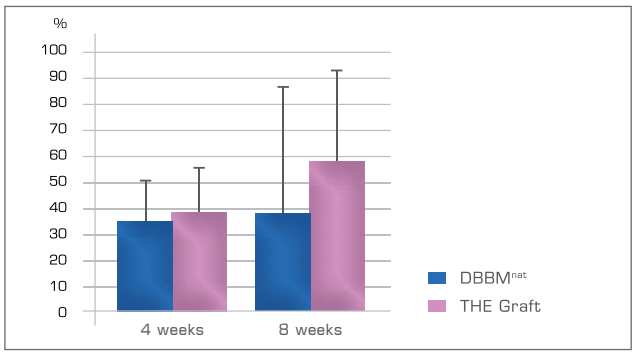


Lamellar/woven bone (bone quality)

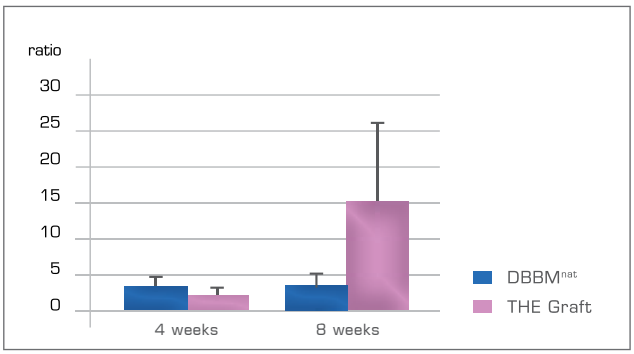


At all time points, THE Graft demonstrated an equal or higher proportion of newly formed vital bone than natural DBBM (left). After 8 weeks, the test group with THE Graft showed a much better bone quality compared with the control group with DBBM illustrated by a higher proportion of lamellar vs. woven bone (right).

# SAFE & BIOCOMPATIBLE

## Optimal safety and biocompatibility profile

The combination of porcine origin with the high level of purity enables predictable bone growth without risking an immunogenic reaction. Thanks to the highly efficient, patented manufacturing process, THE Graft is also completely free from any organic components that could be a potential cause of infection or immune reaction.[6]

The high biocompatibility of THE Graft has been confirmed by an *in-vitro* cell study.[3] THE Graft therefore encourages cell adhesion to the same extent as the established natural DBBM and offers optimal conditions for vital cell growth.

### Cell adhesion

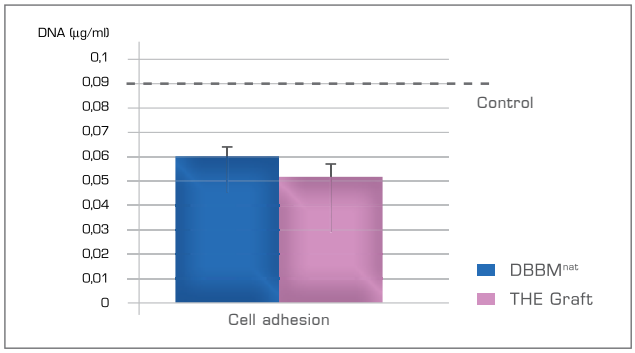


### Cell vitality

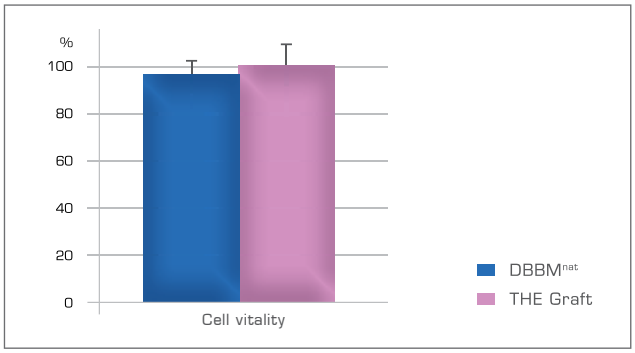


THE Graft demonstrates cell biocompatibility comparable to natural DBBM both in terms of cell adhesion (left) and cell activitiy (right).

# INDICATIONS

## THE Graft as a therapeutic option for successful bone augmentation

THE Graft can be used for the following indications:

| | |
|---|---|
| Augmentation of peri-implant defects<br>(e.g., dehiscence and fenestration defects around implants) | ✓ |
| Filling of extraction sockets | ✓ |
| Sinus lift | ✓ |
| Alveolar ridge augmentation or reconstruction<br>(Guided bone regeneration “GBR” - e.g., lateral/horizontal augmentation) | ✓ |
| Filling of bone defects<br>(e.g., after apicoectomy or cystectomy) | ✓ |
| Filling of periodontal bone defects<br>(e.g., intrabony or furcation defects) | ✓ |

# CLINICAL EVIDENCE – CLINICAL CASE 1

## Augmentation of a dehiscence defect

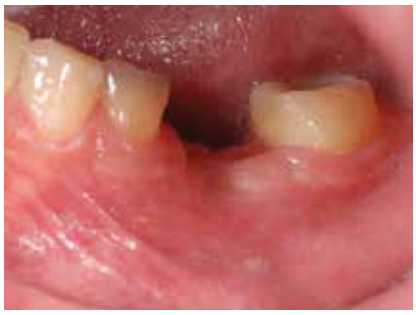

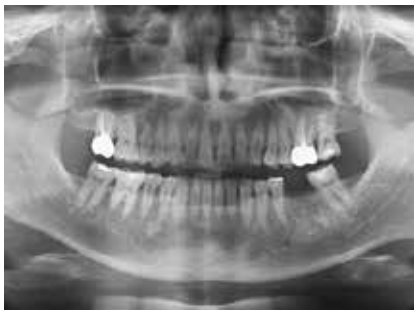

### PRE-OPERATIVE

Situation a few weeks after loss of tooth #36 showing bone deficit in the bucco-crestal aspect.

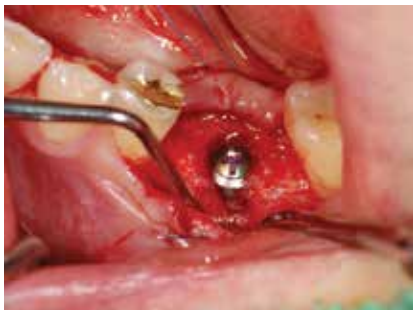

### SURGERY

Situation following flap preparation and implant insertion: dehiscence defect around the implant.

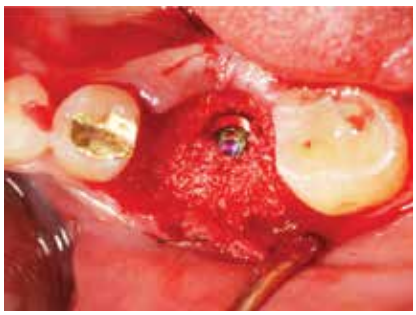

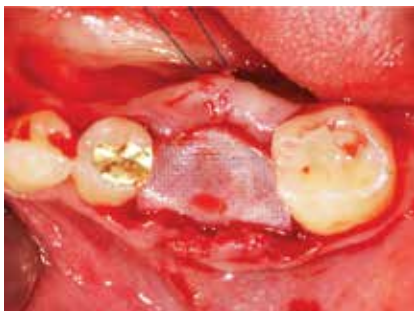

Augmentation of bone defect with THE Graft (left). Covering of bone particle with resorbable collagen membrane (right).

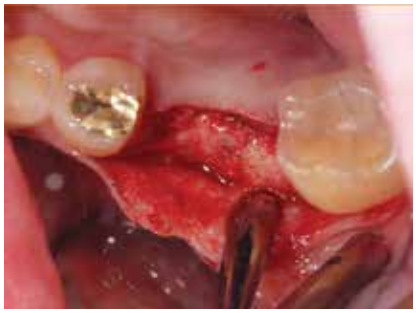

### 4.5 MONTHS POST-OPERATIVE

Situation after re-entry:
Excellent bony consolidation, complete restoration of bone contour around the implant.

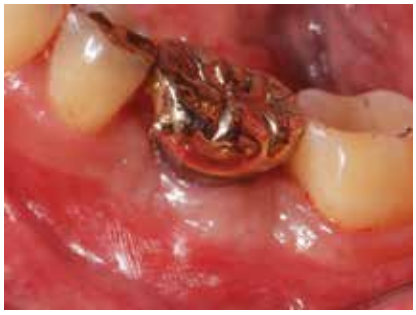

### 6 MONTHS POST-OPERATIVE

Prosthetic final result:
Optimal hard and soft-tissue situation, perfectly contoured bone volume around the implant in #36.

Courtesy of Dr Jun Seok Park, KOR.

# CLINICAL EXPERIENCE – CLINICAL CASE 2

## Complex augmentation in posterior upper jaw

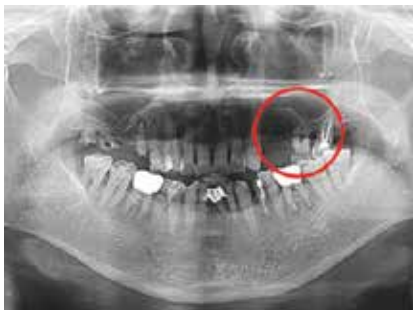

### PRE-OPERATIVE

Severely atrophied posterior upper jaw in second quadrant, teeth #26 and #27 not worth preserving.

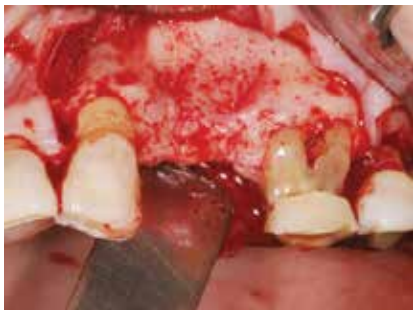

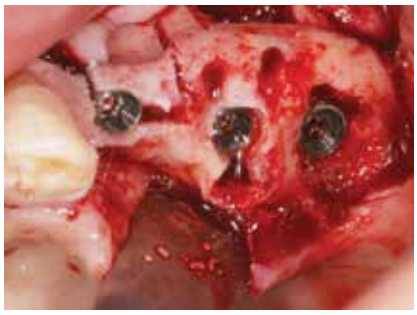

### SURGERY

Extremely narrow alveolar ridge at #24 as well as severe bone resorption at teeth #26 – 27 (left).
Tooth extraction #26 and #27 and preparation of a sinus window at #26. Ridge split at #24 as well as insertion of three implants at #24, 26 and 27 (right).

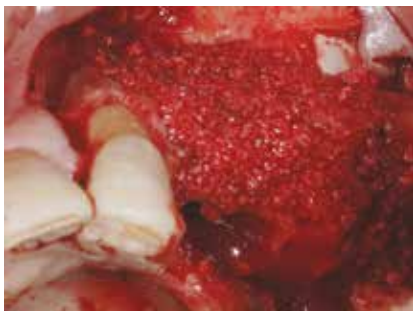

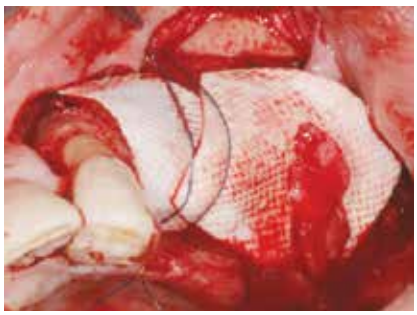

Augmentation of sinus cavity and lateral augmentation in #24 – 27 area with THE Graft (left). Covering with OSSIX® PLUS cross-linked collagen membrane (right).

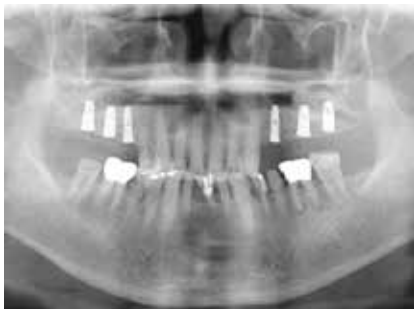

### 5 MONTHS POST-OPERATIVE

Optimal bony consolidation in the previously augmented horizontal dimension #24 – 27 (left) and in the augmented sinus areas #26 – 27 (right).

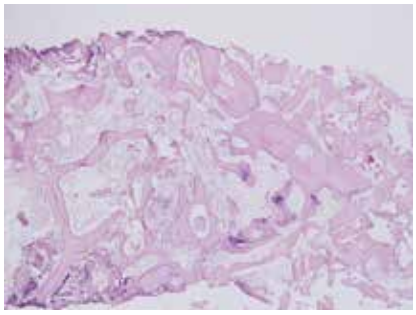

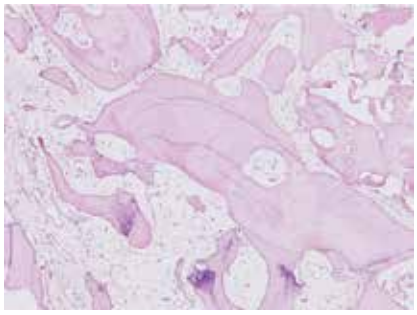

Excellent bony integration of THE Graft in the local bone (left), first signs of slow resorption and replacement by autogenous bone (right).

Courtesy of Dr Dong Hoon Lee, KOR.

# CLINICAL EXPERIENCE – CLINICAL CASE 3

## Lateral augmentation in posterior lower jaw

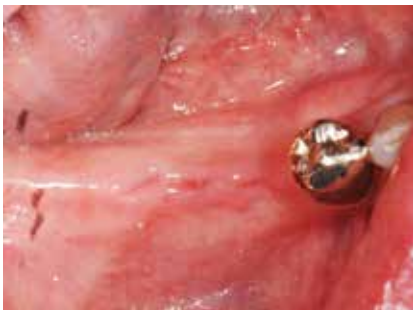

### PRE-OPERATIVE

Severely atrophied posterior lower jaw in #45–47 area.

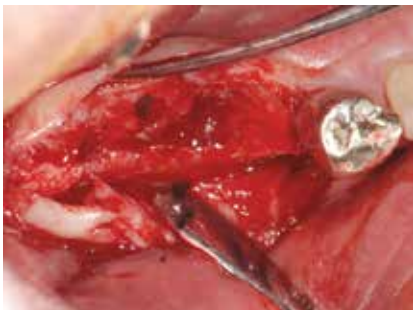

### SURGERY

Situation post flap preparation shows bone deficit at #45–47. Due to the severe atrophy in the bucco-crestal dimension, it is not possible to insert an implant.

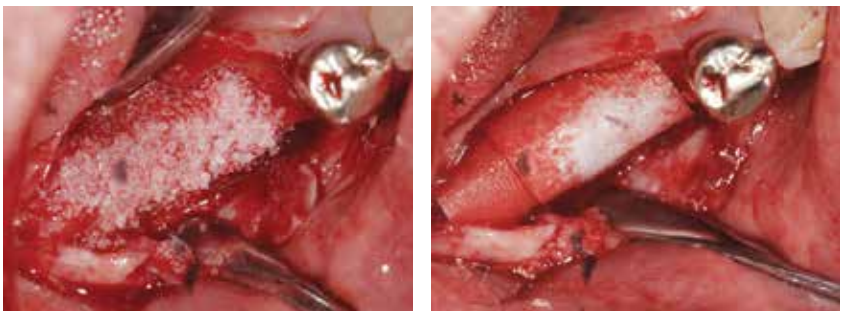

Restoration of the alveolar process at #45–47 with THE Graft (left). Covering of bone particles with resorbable collagen membrane (right).

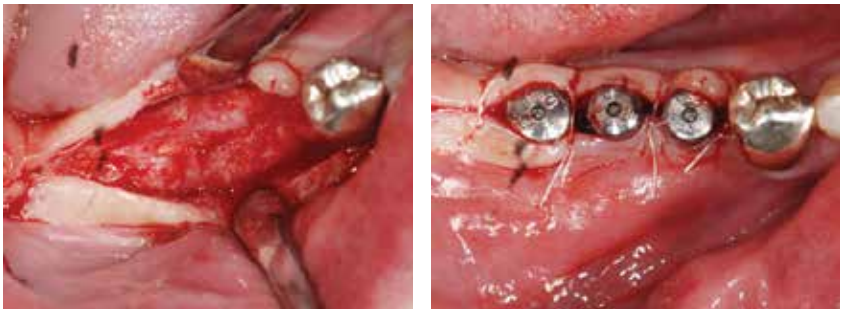

### 4 MONTHS POST-OPERATIVE

Situation on re-entry:
Optimally restored contour of the alveolar process (left), allowing insertion of three implants at #45–47 (right).

Courtesy of Dr Young Joo Jang, KOR.


# AVAILABLE PRODUCTS

| Article number | Granule size | Quantity |
|---|---|---|
| **BG-A25** | 250 – 1000 µm | 0.25 g / **0.6 cc** |
| **BG-A05** | 250 – 1000 µm | 0.5 g / **1.2 cc** |
| **BG-A20** | 250 – 1000 µm | 2.0 g / **4.8 cc** |
| **BG-B05** | 1000 – 2000 µm | 0.5 g / **1.8 cc** |
| **BG-B10** | 1000 – 2000 µm | 1.0 g / **3.6 cc** |

## REFERENCES


1. Pearce A, Richards RG, Milz S, Schneider E, Pearce SG. Animal models for implant biomaterial research in bone: a review. European Cells and Materials 2007;13:1-10.
2. Figueiredo M, Fernando A, Martins G, Freitas J, Judas F, Figueiredo H. Effect of the calcination temperature on the composition and microstructure of hydroxyapatite derived from human and animal bone. Ceramics International 2010;36:2383-2393.
3. Internal test results PURGO, data on file.
4. Lee J-H, Lee E-U, Zhang M-L, Lim H-C, Lim Y-T, Lee J-S, Jung U-W, Choi S-H. Bone regeneration capacity of porcine cancellous bone and porcine-based collagen membrane in rabbit calvarial defects. Biomater. Res. 2013;17(4):160-167.
5. Vanis S, Rheinbach O, Klawonn A, Prymak O, Epple M. Numerical computation of the porosity of bone substitution materials from synthrotron micro computer tomographic data. Mat.-wiss. U. Werkstofftech. 2006;37(6):469-473.
6. Fretwurst T, Spanou A, Nelson K, Wein M, Steinberg T, Stricker A. Comparison of four different allogeneic bone grafts for alveolar ridge reconstruction: a preliminary histologic and biochemical analysis. Oral Surg Oral Med Oral Pathol Oral Radiol 2014;118:424-431.




REGEDENT AG | Zollikerstrasse 144 | CH-8008 Zürich | Tel: +41 (0) 44 700 37 77 | E-Mail: info@regedent.com | www.regedent.com

CE0050 Art. 8114.901EN, 2016-07-15